

Ultrasound as a Useful Tool for a Peripheral Nerve Surgeon: Examples in Clinical Practice

Pathik Aravind, MBBS^{1,*} Rafael Felix P. Tiongco, BA^{1,*} Colton H. McNichols, MD¹ Eric H. Williams, MD^{1,2}

¹Department of Plastic and Reconstructive Surgery, Johns Hopkins University School of Medicine, Baltimore, Maryland

²The Dellon Institutes for Peripheral Nerve Surgery, Towson, Maryland

Address for correspondence Eric H. Williams, MD, The Dellon Institutes for Peripheral Nerve Surgery, 8601 LaSalle Road, Suite 104, Towson, MD 21286 (e-mail: ewilliams@drericwilliams.com).

J Reconstr Microsurg 2023;39:405–412.

Abstract

Background Peripheral nerve surgeons often require additional imaging for examination, diagnostic testing, and preoperative planning. Point-of-care ultrasound (US) is a cost-effective, accessible, and well-established technique that can assist the surgeon in diagnosing and treating select peripheral nerve pathologies. With this knowledge, the properly trained surgeon may perform US-guided nerve blocks to help accurately diagnose and treat causes of neuropathic pain. We offer this paper, not as an exhaustive review, but as a selection of various peripheral nerve pathologies, which the senior author treats, and their associated US examination findings. Our goal is to encourage other peripheral nerve surgeons to incorporate US into their practices.

Methods We provide various cases from our outpatient peripheral nerve clinic demonstrating relevant US anatomy. We also review techniques for US guided nerve blocks with relevant anatomic landmarks.

Results US imaging successfully assisted in identification and injection techniques for various peripheral nerve pathologies in a surgeon's practice. Examples were presented from the neck, trunk, upper extremity, and lower extremity.

Conclusion Our review highlights the use of US by a peripheral nerve surgeon in an outpatient private practice clinic to diagnose and treat select peripheral nerve pathologies. We encourage reconstructive surgeons to add US to their arsenal of diagnostic tools.

Keywords

- ▶ ultrasound
- ▶ peripheral nerve
- ▶ peripheral nerve surgery

Peripheral nerve surgery is an integral component of a reconstructive microsurgeon's knowledge base. As the field of peripheral nerve surgery grows, so does the need for easily accessible, cost-effective, and accurate diagnostic tools. Point-of-care ultrasound (US) can meet this need in a subset of patients with chronic neuropathic pain, and the authors have found US to be indispensable in the diagnosis and treatment of such. US is a widely available, cost-effective, and well-established imaging modality that can provide real-time imaging of many common peripheral nerve pathologies.^{1–3} Reconstructive microsurgeons, after appropriate training, may use US in the office and interpret results during

examination, which has multiple benefits to their clinical practices and patients. The purpose of this article is not to provide a comprehensive review of nerve anatomy, but instead to present select examples of common peripheral nerve pathologies and US exam findings from the senior author's peripheral nerve clinic. Our goal is to encourage surgeons to explore the use of US in their own practices for appropriate indications.

Appearance of Nerves on Ultrasound and Tips to Assess for Nerve Pathology

Nerves have a characteristic appearance on US and a proper examination should include transverse and longitudinal scanning.⁴ On transverse sonograms, normal nerves show echotextures of tiny hypoechoic dots, representing the

* These authors contributed equally in the writing of this manuscript.

received

April 16, 2022

accepted after revision

October 5, 2022

article published online

December 30, 2022

© 2022, Thieme. All rights reserved.
Thieme Medical Publishers, Inc.,
333 Seventh Avenue, 18th Floor,
New York, NY 10001, USA

DOI <https://doi.org/10.1055/s-0042-1759526>.
ISSN 0743-684X.

meshwork of connective tissue, surrounded by fascicles and superficial epineurium; often this is described as a “honeycomb appearance.”⁴ On longitudinal sonograms, nerves present as bands with a mixture of hyperechoic (peri- and epineurium) and hypoechoic elements (fascicle groups). Notably, the overall number of fascicles visualized does not correspond directly to the true number due to merging of adjacent fascicles in a single image.⁵

When examining nerves with US, it is important to scan the nerve’s length to compare its size and appearance along its expected course. Any abrupt change in size or echotexture would signal the need to investigate further as it may represent a pathologic process. In cases of open trauma or in locations with previous surgical incisions, nerves may be difficult to identify at the site of interest due to scar tissue buildup. Visualizing the nerve at an uninjured portion before following it to the site of injury may be helpful. Comparison to the contralateral nerve may aid in assessing for pathologic changes as well.

Clinical Examples from the Author’s Practice

Head and Neck

Greater Occipital Nerve and Lesser Occipital Nerve

Greater occipital nerve (GON) compression commonly presents as an occipital or cervicogenic headache with symptoms often overlapping with migraines.^{6–8} Patients complain of a sharp, shooting, and stabbing pain radiating from the suboccipital region to the vertex.⁷ Lesser occipital nerve (LON) compression presents similarly but tends to be more lateral, which correlates with its anatomical course.^{9,10} The GON and LON may be blocked separately to help in the differential diagnosis.

US Examination

The patient may be positioned prone or seated with neck in flexion. The probe is placed horizontally across the occipital ridge and the GON can be identified medial to the occipital

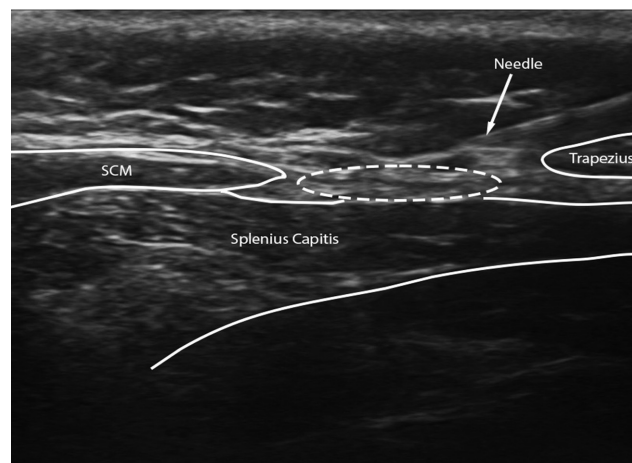


Fig. 1 Transverse view of the lesser occipital nerve (LON) on ultrasound mid-injection. The LON is within the white dashed oval. The pre-injection image can be found in **–Supplementary Fig. S2**. Anatomical landmarks such as the sternocleidomastoid (SCM), splenius capitis, and trapezius are included.

artery. The GON may be located closer to its origin. One can place the probe at C2 and travel cephalad along the course of the GON to identify the nerve above the inferior oblique capitis muscle. Symptomatic patients have been reported to show significantly greater cross-sectional area (CSA) versus normal.¹¹ The senior author finds it easiest to block the GON between the trapezius and semispinalis capitis. However, the block is placed within the semispinalis capitis muscle as the GON travels through the muscle belly (**–Supplementary Fig. S1**, available in the online version).

The smaller LON is more difficult to see but can be blocked separately, even when not visualized, based on easily identifiable anatomical landmarks seen on US. The author prefers to perform a field block of the LON at the lower edge of the mastoid process to capture all anatomical variations. By blocking on the surface of the neck musculature from the lateral edge of the trapezius over the splenius and the posterior border of the sternocleidomastoid, the spinal accessory nerve can be avoided as well (**–Fig. 1, –Supplementary Figs. S2–S4**, available in the online version).¹² Of note, the author has used US to block other peripheral nerves in the neck including the greater auricular nerve, auriculotemporal nerve, and cervical plexus.

Upper Extremity

Median Nerve

US is known to be a painless and accurate diagnostic tool for carpal tunnel syndrome (CTS), which is extensively described in the literature.^{13–15} Previous papers have measured the CSA of the median nerve at the level of the lunate and suggest that a CSA greater than 10 to 12 mm² correlates with the diagnosis of CTS in symptomatic patients.¹⁶

US Examination

Patients with CTS present with classic signs of paresthesia in the distribution of the median nerve, with or without weakness of median-innervated thenar muscles. The most common source of pathology can be identified at the wrist by viewing the carpal tunnel (**–Supplementary Fig. S5**, available in the online version). Sonography along the length of the nerve is sometimes more beneficial than a snapshot in a single location or plane. US is also quite useful when performing therapeutic steroid injections.¹⁷

The median nerve may also become entrapped proximally to the carpal tunnel, and a thorough US examination should investigate proximal entrapment if indicated. At the elbow, the median nerve can be entrapped at (1) the distal humerus by the ligament of Struthers, (2) proximal elbow by a thickened biceps aponeurosis, (3) just distal to the elbow between the superficial and deep heads of the pronator teres muscle, and (4) the proximal forearm by a thickened proximal edge of the flexor digitorum superficialis muscle.¹⁸

Ulnar Nerve

The cubital tunnel is a well-known location for ulnar nerve compression that results in cubital tunnel syndrome (CUTS).¹⁸ Patients present with paresthesia and numbness

to the ulnar side of the forearm and hand, and weakness of grip and coordination.¹⁸ Ulnar nerve compression may also be seen at the wrist (Guyon's canal) with similar presentation but without numbness over the dorsum of the hand.

US Examination

Due to its large diameter, superficial course, and characteristic location, the ulnar nerve is easily visualized with US. It is best to begin at the post-condylar groove for CUTS, applying the probe transversely and then scanning proximally or distally (► **Supplementary Fig. S6** (available in the online version), ► **Supplementary Video 1**). For diagnosing ulnar neuropathy, previous studies give CSA thresholds of 9 mm² at the maximum swelling point of the nerve.¹⁹ Reference points such as the brachial artery, triceps brachii, and flexor carpi ulnaris may be useful in identification.²⁰

Video 1

Transverse view of the ulnar nerve at the elbow with changes in fascicular architecture seen in cross-section showing abnormality of the nerve after in situ decompression and accessory muscle resection. We show the nerve as it travels through the cubital tunnel. Online content including video sequences viewable at: <https://www.thieme-connect.com/products/ejournals/html/10.1055/s-0042-1759526>.

The authors found that US may aid in the diagnosis of medial arm pain after previous ulnar nerve transposition or other surgery to the area. The surgeon may separately evaluate the appearance and location of the ulnar nerve and the more superficial branches of the medial antebrachial cutaneous nerve (MABCN) and medial brachial cutaneous nerve (MBCN; ► **Fig. 2**). US may be helpful in determining whether the more superficial branches may be entrapped in the incision of surrounding scar tissue causing neuroma

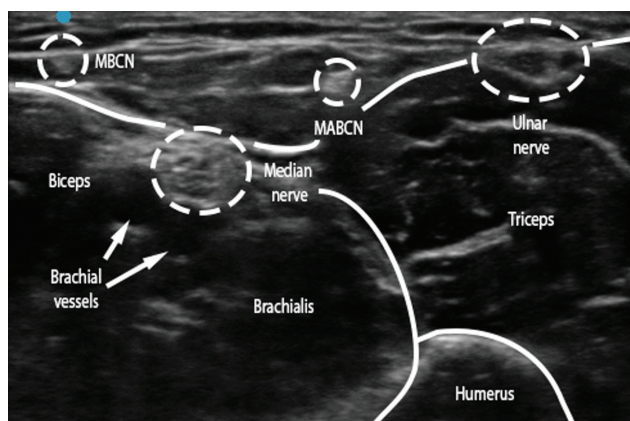


Fig. 2 Ultrasound view of the medial antebrachial cutaneous nerve (MABCN), medial brachial cutaneous never (MBCN), ulnar, and median nerves. Probe was positioned on the distal third of the anterior surface of the arm. Anatomical landmarks include the biceps. Brachial vessels are seen as well and are compressible on examination.

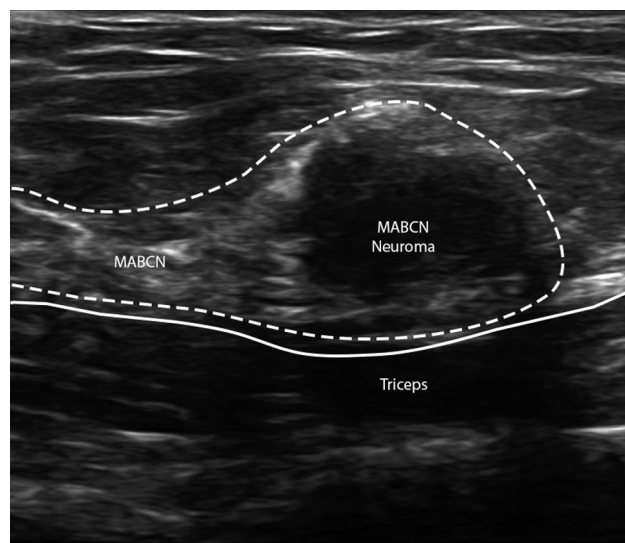


Fig. 3 Longitudinal view of the medial antebrachial cutaneous nerve (MABCN) with a stump neuroma. There is an abrupt change in cross-sectional area and echotexture of the neuroma versus the healthy portion of the nerve. These changes can be seen within the white dashed lines. The triceps brachii muscle is used as an anatomical landmark to identify this nerve. The white solid line represents fascia.

pain. The senior author has successfully utilized US in the clinic to identify differential causes of medial elbow pain of neuropathic origin with sequential blocks of the MABCN, MBCN, and the ulnar nerve (► **Fig. 3**, ► **Supplementary Figs. S7** and **S8**, available in the online version). Though US-guided blocks may provide pain relief, findings of a Z-shaped deformity or sudden change in caliber of the ulnar nerve, associated with a fascial or muscle sling, may be an indication for surgery.²¹

Radial Nerve and Branches

The radial nerve originates from the posterior cord of the brachial plexus, passes through the triangular interval, and travels caudally within the spiral groove of the humerus. Bifurcation into the deep branch of the radial nerve (DBRN) and the radial sensory nerve (RSN) occurs near the level of the radiocapitellar joint. The DBRN can be compressed in the arcade of Frohse (supinator arch), which is the fibrous entrance to the space between the superficial and deep layers of the supinator; this is known as “radial tunnel syndrome” (RTS).²² RTS patients may present with an achy pain in the lateral dorsal elbow and with weakness of digit extension and wrist extension.^{23–25} Patients who have an isolated compression of the RSN may present with radial wrist pain and paresthesia into the first web space.²⁶ The RSN travels under the brachioradialis muscle and subsequently exits into the subcutaneous tissue between the brachioradialis tendon and the tendon of the extensor carpi radialis longus which is the typical location of compression.²⁶

US Examination

The radial nerve may be assessed for both focal and diffuse enlargement along its course. US can be used to follow the

course of the radial nerve of patients complaining of pain in the radial distribution of the upper arm (► **Supplementary Fig. S9**, available in the online version). More caudally, the DBRN which is usually the target for injections, can be located near a focal flattening and proximal swelling between the superficial and deep heads of the supinator. Surgeons may be able to confirm and treat RTS due to DBRN compression with US-guided nerve blocks.

In cases of lateral elbow pain suspected to be of neuropathic origin, US examination allows the physician to independently block the posterior cutaneous nerve of the forearm and radial nerve in the radial tunnel to narrow the differential diagnosis.

The authors have also found US useful in patients with distal radial wrist pain of neuropathic origin such as injury of the lateral antebrachial cutaneous nerve (LABCN) and RSN (► **Fig. 4**). The LABCN is known to overlap with the RSN.²⁷ The LABCN travels superficial to the brachioradialis while the RSN runs deep until the distal forearm where the two nerves may travel close to one another (► **Fig. 5**, ► **Supplementary Fig. S10**, available in the online version).²⁷ Performing sequential US-guided nerve blocks of these branches would be most helpful to the peripheral nerve surgeon when evaluating patients who present with radial arm or dorsoradial wrist pain (► **Supplementary Fig. S11**, available in the online version). Other potential uses in the clinic may include hydrodissection of the nerve for Wartenberg syndrome.

Trunk

Ilioinguinal and Iliohypogastric Nerve

Ilioinguinal nerve (IIN) and iliohypogastric nerve (IHN) entrapment or injury most commonly presents after inguinal hernia repairs, cesarean sections, panniculectomies, abdominoplasties, and other procedures requiring exposure to the lower quadrants. Patients may describe a sharp, stabbing, electrical shooting pain or a burning hypersensitivity to the groin and suprapubic region sparing the genitals. IIN and IHN entrapment can be diagnosed with the triad of pain in the area of nerve distribution, dysesthesia, and improvement of pain after nerve block.²⁸ The pain is typically elicited with

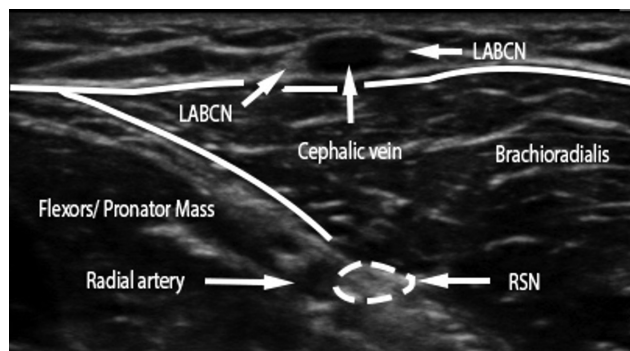


Fig. 4 Normal view of the lateral antebrachial cutaneous nerve (LABCN) at the proximal forearm. The LABCN surrounds the cephalic vein as it travels caudally to provide sensory innervation to the skin of the lateral forearm. The brachioradialis and flexor wad are seen as landmarks in this static image. The radial sensory nerve (RSN) can be seen traveling within the brachioradialis as well prior to emerging from its muscle belly in the mid-distal forearm.

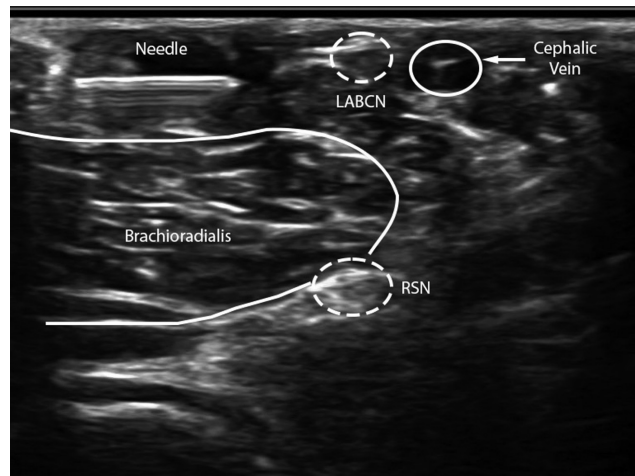


Fig. 5 Example of a differential block of the lateral antebrachial cutaneous nerve (LABCN) and the radial sensory nerve (RSN) in the patient complaining of radial forearm pain in ► **Supplementary Fig. S10**. Images are in transverse view. The needle is shown depositing a bolus of anesthetic. Anatomical landmarks include the cephalic vein, which is compressible on examination, and brachioradialis muscle.

pressure medial to the anterior superior iliac spine (ASIS) and lateral to the rectus border above the inguinal ligament.

US Examination

The IIN and IHN can be most easily visualized at the ASIS from the internal oblique muscle to the transversalis fascia.²⁹ However, since these nerves are quite small, have variable locations, and often contain multiple branches, the author prefers to use anatomical landmarks to guide the injection as opposed to identifying the nerves themselves (► **Supplementary Fig. S12**, available in the online version). The author typically places a probe obliquely to the ASIS,

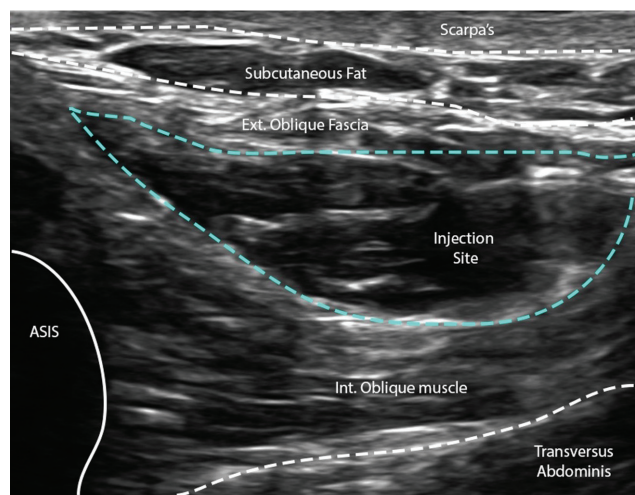


Fig. 6 Transverse view of the ilioinguinal and iliohypogastric nerve (IIN and IHN) plane postinjection. Within the blue dashed lines is a bolus of anesthetic after a successful nerve block in the plane containing the IIN/IHN. The anatomical landmarks of Scarpa's fascia, subcutaneous fat, the external oblique fascia, internal oblique muscle, anterior superior iliac spine (ASIS), and transversus abdominis muscle are critical to identifying this plane. Fascial planes are represented by white dashed lines. The border of the ASIS is represented by the white solid line.

injecting in the plane between the internal oblique and external oblique fascia proximal to any site of injury (► **Fig. 6**). This block utilizes a bubble of anesthetic that spreads to block both the IIN and IHN.

Genitofemoral Nerve

Patients with genitofemoral nerve (GFN) entrapment present with intermittent or constant pain, often aggravated with activity, and paresthesias in the groin, scrotum, testicle/labia majora, and inner/proximal thigh.³⁰ We most often see this GFN entrapment in previous hernia repairs or previous procedures or trauma in and around the groin.

US Examination

The genital branch is slender and hard to visualize, particularly in women. However, by first identifying the external iliac artery at the inguinal canal, the genital branch may be present inferior and lateral to the spermatic cord or the round ligament in the inguinal canal.³¹ We start with a perpendicularly placed linear probe over the inguinal ligament 1 to 2 fingerbreadths lateral to the pubic tubercle. Travelling cephalad, the juncture between the external iliac and the femoral artery is identified. In men, visualization of the spermatic cord can further aid in injection placement because the GFN tends to run inferolateral to the cord and then courses through the inguinal canal just deep to the cord. The distinct anatomy of the GFN allows us to distinguish it from the IIN, which tends to run on top of the cord. When assessing the differential diagnosis of chronic inguinal pain with or without testicular pain, we find it more practical to block the IIN and IHN at the ASIS first. If pain remains, then we place a generous bolus of anesthetic inferolateral to the spermatic cord often creating a “halo” of anesthetic fully blocking the genital branch of the GFN (► **Supplementary Fig. S13**).

Lower Extremity

Superficial and Deep Peroneal Nerves

The common peroneal nerve splits at the level of the knee into the superficial and deep peroneal nerves (SPN/DPN) which travel to the dorsum of the foot. In our clinic, we see many patients who either have nerve compressions or possible nerve injuries resulting in neuromas or neuromas-in-continuity. We found that performing our own blocks can be very helpful.

The SPN provides motor branches to the peroneus longus and brevis, and courses distally to provide cutaneous sensation to the lateral aspect of the leg and dorsum of the foot. In 25% of patients, there will be a branch of the SPN in the anterior compartment. Some patients will also have a branch in both anterior and posterior compartments due to a high bifurcation of the nerve.³² The SPN is most frequently compressed at the mid-leg where it exits the crural fascia from the lateral compartment and becomes subcutaneous 8 to 12 cm proximal to the tip of the lateral malleolus.³² Patients with SPN entrapment complain of pain, tingling, and paresthesias along the anterolateral aspect of the leg and the dorsum of the foot.³²

The DPN is less commonly injured than the SPN. However, the lateral and medial branches of the DPN may become entrapped while coursing across the ankle joint and toward the first web space, respectively.^{33–35} Entrapment most commonly occurs under the extensor hallucis brevis tendon.³¹ Patients typically present with pain in the first web space to the lateral ankle and may have weakness in dorsiflexion. However, symptoms depend on the location of the nerve injury.³⁵ In our experience, patients who suffer crush injuries to the foot typically do not experience weakness as opposed to those with tibia or fibula fractures.

US Examination

The SPN can be visualized by placing the probe over the intermuscular septum between the anterior and lateral compartments about 12 cm distal to the knee (► **Fig. 7**, ► **Supplementary Fig. S14**, available in the online version).³³ One can move the probe toward the ankle and identify the SPN emerging from the fascia into the subcutaneous tissue. The examiner may then follow the course of the nerve to identify points of interest that are suspicious for nerve pathology. In our clinic, the author performs differential blocks of the SPN including the main, anterior, and lateral branches as necessary, each of which may be visualized on US.

Visualization of the DPN begins by placing the probe on the ventral aspect of the ankle joint in a transverse orientation 1 to 2 cm proximal to the level of the medial and lateral malleoli.^{36,37} The DPN can be seen as a small “honeycomb” structure several millimeters in size and adjacent to the anterior tibial vessels (► **Supplementary Fig. S15**, available in the online version).

For patients presenting with dorsal foot pain, we typically perform US-guided blocks starting with the nerve eliciting the most pain and assess for improvement. If pain persists, a subsequent block is performed in a different region. To ensure

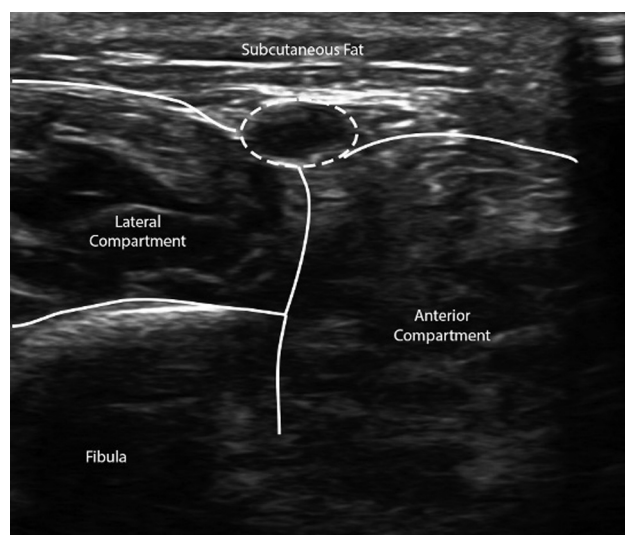


Fig. 7 Transverse view of the superficial peroneal nerve (SPN) on ultrasound-guided examination. The SPN is within the white dashed circle. Anatomical landmarks include subcutaneous fat, the anterior compartment of the leg, the lateral compartment of the leg, and the fibula.

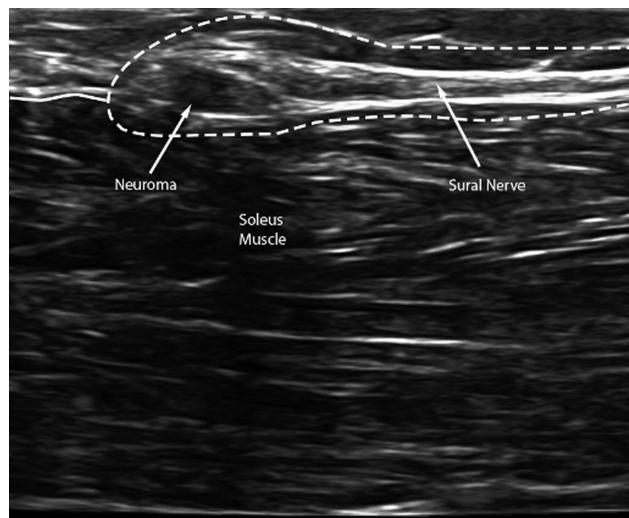


Fig. 8 Longitudinal view of the sural nerve with a neuroma. The sural nerve and neuroma are within the white dashed lines. The enlarged, hypoechoic area is a pathologic finding that is most likely a neuroma. The soleus muscle is used as an anatomical landmark. The white solid line represents fascia.

a proper differential nerve block, the initial injection must be proximal to the site of injury where the nerves do not overlap. For example, the author may first block the SPN on the surface of the fascia in the mid-leg, and if pain is not relieved, then block the DPN deep in the anterior compartment.

Sural Nerve

Injury or compression to the lateral sural nerve (LSN), medial sural nerve (MSN), or main sural nerve may occur throughout their course due to trauma or surgical procedures such as varicose vein removal, gastrocnemius lengthening, or ankle reconstruction.³⁸

US Examination

One may begin by placing the probe at the ankle, where the sural nerve can be easily identified as a single branch intimately associated with the small saphenous vein. Moving cephalad, the sural nerve can be seen splitting into the LSN, which travels on top of the lateral gastrocnemius, and the MSN, which travels between the two heads of the gastrocnemius.³⁹ In the mid-calf, the communicating branch of the LSN splits from the main sural nerve and connects to the LSN proper. Travelling further cephalad, one can frequently identify additional branches from the LSN as they join with the common peroneal nerve in the popliteal fossa. The MSN can be followed in the raphe to join the tibial nerve between the heads of the gastrocnemius.

Our practice has been able to use US-guided blocks of the sural nerve at various locations to identify neuromas, and to sequentially block the independent branches of the sural nerve according to patients' pain patterns (– Fig. 8, – Supplementary Figs. S16 and S17, available in the online version).

Tibial Nerve

The tibial nerve branches from the sciatic nerve and traverses the posterior leg laying deep to the soleus in the deep

posterior compartment. Within its tarsal tunnel, the tibial nerve is deep to the flexor retinaculum, travelling between the Achilles tendon and the posterior tibia with the tibial vessels.^{40–42} The posterior tibial nerve is separated from the deep tendons by the fascia of the deep posterior compartment.

The tibial nerve branches into the medial plantar, lateral plantar, and inferior calcaneal nerves as it travels under the abductor hallucis longus through the three distinct tarsal tunnels.⁴³ The medial calcaneal branch, the much smaller branch analogous to the palmar cutaneous branch in the hand, splits from the tibial nerve and travels above the abductor hallucis longus.^{43,44}

US Examination

The tibial nerve and its branches can be scanned from the popliteal fossa to the inner ankle and through the four tarsal tunnels using both transverse and longitudinal views. The nerve can be identified adjacent to the tibial vessels as it travels through the deep posterior compartment. The author finds that the tibial nerve is easier to identify as it becomes more superficial in the ankle. From there, the examiner can follow the nerve proximally and distally to evaluate for changes of size and fascicular architecture of the nerve throughout its entire course (– Supplementary Figs. S18–S21, available in the online version).

Within the tunnel, the probe should be manipulated to maintain a perpendicular orientation to the tibial nerve. While anatomy is variable, the nerve is most commonly located posteroinferiorly to the vessels. As one follows the tibial nerve downstream, one can observe the tibial nerve split into the medial plantar nerve, lateral plantar nerve, and inferior calcaneal nerve; one may block each branch independently if necessary.

Discussion

We present the experience of the senior author's use of US in a peripheral nerve clinic and a few, notable pathologies typically encountered in the practice. There are many advantages of performing US in clinic. Anatomical studies demonstrate variation in nerve anatomy which can affect clinical presentation and surgical treatment.^{27,31,33} Surgeons are uniquely situated to utilize this technology as their intra-operative knowledge of these same nerves heightens their awareness of anatomical variations. Therefore, we believe that most surgeons will quickly see the value of US examination, after undergoing necessary training, for preoperative planning and performing diagnostic nerve blocks that they would typically refer to other colleagues.

Additionally, surgeons who perform US-guided blocks can immediately identify their effectiveness, and based on that information, can develop better treatment plans. Patients often report immediate relief of pain if the precise nerve is anesthetized. In the context of preoperative planning, real-time feedback may be superior to delays in diagnosis or potential for miscommunications when these injections are performed at other clinics. These facts may make the

properly trained peripheral nerve surgeon uniquely prepared to prevent missed injections or misdiagnoses of neuropathic causes of chronic pain.

We also cannot ignore the financial benefits to both the surgeon and the patient. US-guided examinations and procedures are reimbursable to physicians. A recent cost-benefit study by Huynh et al showed that the initial cost of the US machine can be justified by a potential long-term financial return over 10 years.⁴⁵ Use of US by the surgeon is also more cost-effective for patients. Since these procedures can be performed in the surgeon's office, patients would save on supplementary consultation costs, fees, and time associated with scheduling and travel to other specialists. Finally, this streamlined approach to care further strengthens the patient-physician relationship.

The scope of US as a diagnostic tool is well-established as duplex US has been shown to be a powerful tool for perforator flap design^{46,47} and for supermicrosurgery.⁴⁸ We add that surgeons, mainly peripheral nerve surgeons, may use US as a therapeutic-adjunct tool in their clinics as well. Despite the benefits of US, there remains limited exposure to its full potential for surgical trainees or the practicing reconstructive microsurgeon. Incorporating didactic sessions for US-guided diagnosis of peripheral nerve pathologies and hands-on training for US-guided nerve blocks would greatly benefit surgical residency curricula. There are also many well-designed US courses conducted regularly by established medical societies that cover information relevant to one's clinical needs.⁴⁹ We encourage reconstructive microsurgeons who are interested in expanding their skillset to look toward US.

Conclusion

Our review highlights the use of US by a peripheral nerve surgeon for diagnosis and treatment of select peripheral nerve pathologies in an outpatient private practice clinic. We believe US is advantageous for the peripheral nerve surgeon, who is ideally suited to perform many of these examinations. We highly encourage residency programs to increase trainee exposure to US in peripheral nerve surgery and encourage practicing reconstructive surgeons to seek appropriate training with hands-on US workshops specifically tailored to their clinical needs.

Conflict of Interest

None declared.

References

- Peer S. High-Resolution Sonography of the Peripheral Nervous System. Germany: Springer; 2010
- Willsey M, Wilson TJ, Henning PT, Yang LJ-S. Intraoperative ultrasound for peripheral nerve applications. *Neurosurg Clin N Am* 2017;28(04):623–632
- Strakowski JA. Ultrasound-guided peripheral nerve procedures. *Phys Med Rehabil Clin N Am* 2016;27(03):687–715
- Kowalska B, Sudoł-Szopińska I. Normal and sonographic anatomy of selected peripheral nerves. Part I: sonohistology and general principles of examination, following the example of the median nerve. *J Ultrason* 2012;12(49):120–130
- Stuart RM, Koh ES, Breidahl WH. Sonography of peripheral nerve pathology. *AJR Am J Roentgenol* 2004;182(01):123–129
- Waldman SD. Pain Management. Philadelphia: Saunders/Elsevier; 2007
- Janis JE, Hatef DA, Ducic I, et al. The anatomy of the greater occipital nerve: part II. Compression point topography. *Plast Reconstr Surg* 2010;126(05):1563–1572
- Mosser SW, Guyuron B, Janis JE, Rohrich RJ. The anatomy of the greater occipital nerve: implications for the etiology of migraine headaches. *Plast Reconstr Surg* 2004;113(02):693–697, discussion 698–700
- Ducic I, Felder JM III, Khan N, Youn S. Greater occipital nerve excision for occipital neuralgia refractory to nerve decompression. *Ann Plast Surg* 2014;72(02):184–187
- Peled ZM, Pietramaggiore G, Scherer S. Anatomic and compression topography of the lesser occipital nerve. *Plast Reconstr Surg Glob Open* 2016;4(03):e639
- Cho JC, Haun DW, Kettner NW. Sonographic evaluation of the greater occipital nerve in unilateral occipital neuralgia. *J Ultrasound Med* 2012;31(01):37–42
- Platzgummer H, Moritz T, Gruber GM, et al. The lesser occipital nerve visualized by high-resolution sonography—normal and initial suspect findings. *Cephalalgia* 2015;35(09):816–824
- Yoshii Y, Zhao C, Amadio PC. Recent advances in ultrasound diagnosis of carpal tunnel syndrome. *Diagnostics (Basel)* 2020;10(08):596
- El Miedany YM, Aty SA, Ashour S. Ultrasonography versus nerve conduction study in patients with carpal tunnel syndrome: substantive or complementary tests? *Rheumatology (Oxford)* 2004;43(07):887–895
- Pimentel BFR, Faloppa F, Tamaoki MJS, Belloti JC. Effectiveness of ultrasonography and nerve conduction studies in the diagnosing of carpal tunnel syndrome: clinical trial on accuracy. *BMC Musculoskelet Disord* 2018;19(01):115
- Takata SC, Kysh L, Mack WJ, Roll SC. Sonographic reference values of median nerve cross-sectional area: a protocol for a systematic review and meta-analysis. *Syst Rev* 2019;8(01):2
- Lauretti L, D'Alessandris QG, De Simone C, et al. Ulnar nerve entrapment at the elbow. A surgical series and a systematic review of the literature. *J Clin Neurosci* 2017;46:99–108
- Miller TT, Reinus WR. Nerve entrapment syndromes of the elbow, forearm, and wrist. *AJR Am J Roentgenol* 2010;195(03):585–594
- Kim JH, Won SJ, Rhee WI, Park HJ, Hong HM. Diagnostic cutoff value for ultrasonography in the ulnar neuropathy at the elbow. *Ann Rehabil Med* 2015;39(02):170–175
- Mezian K, Jačisko J, Kaiser R, et al. Ulnar neuropathy at the elbow: from ultrasound scanning to treatment. *Front Neurol* 2021;12:661441
- Rogers MR, Bergfield TG, Aulicino PL. The failed ulnar nerve transposition. Etiology and treatment. *Clin Orthop Relat Res* 1991;(269):193–200
- Shamrock AG, Das JM. Radial Tunnel Syndrome. [Updated August 25, 2021]. In: StatPearls [Internet] Treasure Island, FL: StatPearls Publishing; 2022
- Kowalska B, Sudoł-Szopińska I. Normal and sonographic anatomy of selected peripheral nerves. Part II: peripheral nerves of the upper limb. *J Ultrason* 2012;12(49):131–147
- Ljungquist KL, Martineau P, Allan C. Radial nerve injuries. *J Hand Surg Am* 2015;40(01):166–172
- Ceri T, Podda A, Behr J, Brumpt E, Alilet M, Aubry S. Posterior interosseous nerve of the elbow at the arcade of Frohse: ultrasound appearance in asymptomatic subjects. *Diagn Interv Imaging* 2019;100(09):521–525
- Anthony JH, Hadeed A, Hoffer CE. Cheiralgia Paresthetica. [Updated July 28, 2021]. In: StatPearls [Internet] Treasure Island, FL: StatPearls Publishing; 2022

- 27 Mackinnon SE, Dellon AL. The overlap pattern of the lateral antebrachial cutaneous nerve and the superficial branch of the radial nerve. *J Hand Surg Am* 1985;10(04):522–526
- 28 Stulz P, Pfeiffer KM. Peripheral nerve injuries resulting from common surgical procedures in the lower portion of the abdomen. *Arch Surg* 1982;117(03):324–327
- 29 Toussaint CP, Perry EC III, Pisansky MT, Anderson DE. What's new in the diagnosis and treatment of peripheral nerve entrapment neuropathies. *Neuro Clin* 2010;28(04):979–1004
- 30 Gofeld M, Christakis M. Sonographically guided ilioinguinal nerve block. *J Ultrasound Med* 2006;25(12):1571–1575
- 31 Rab M, Ebmer And J, Dellon AL. Anatomic variability of the ilioinguinal and genitofemoral nerve: implications for the treatment of groin pain. *Plast Reconstr Surg* 2001;108(06):1618–1623
- 32 Soneji N, Peng PW. Ultrasound-guided pain interventions - a review of techniques for peripheral nerves. *Korean J Pain* 2013;26(02):111–124
- 33 Ducic I, Dellon AL, Graw KS. The clinical importance of variations in the surgical anatomy of the superficial peroneal nerve in the mid-third of the lateral leg. *Ann Plast Surg* 2006;56(06):635–638
- 34 Allam AE, Mansour ER. Superficial Peroneal Nerve Block. [Updated November 21, 2021]. In: StatPearls [Internet] Treasure Island, FL: StatPearls Publishing; 2022
- 35 Dellon AL. Deep peroneal nerve entrapment on the dorsum of the foot. *Foot Ankle* 1990;11(02):73–80
- 36 Fortier LM, Markel M, Thomas BG, Sherman WF, Thomas BH, Kaye AD. An update on peroneal nerve entrapment and neuropathy. *Orthop Rev (Pavia)* 2021;13(02):24937
- 37 Fletcher T, Orgill BD, Barth B. Deep Peroneal Nerve Block. [Updated September 18, 2021]. In: StatPearls [Internet] Treasure Island, FL: StatPearls Publishing; 2022
- 38 Pomeroy G, Wilton J, Anthony S. Entrapment neuropathy about the foot and ankle: an update. *J Am Acad Orthop Surg* 2015;23(01):58–66
- 39 Bianchi S, Droz L, Lups Deplaine C, Dubois-Ferriere V, Delmi M. Ultrasonography of the sural nerve: normal and pathologic appearances. *J Ultrasound Med* 2018;37(05):1257–1265
- 40 Chang KV, Mezian K, Naňka O, et al. Ultrasound imaging for the cutaneous nerves of the extremities and relevant entrapment syndromes: from anatomy to clinical implications. *J Clin Med* 2018;7(11):457
- 41 Yates B. Merriman's Assessment of the Lower Limb E-Book. Edinburgh, Scotland: Churchill Livingstone, 2012
- 42 Harries M. Oxford Textbook of Sports Medicine. New York: Oxford University Press; 1996
- 43 Dellon AL, Mackinnon SE. Tibial nerve branching in the tarsal tunnel. *Arch Neurol* 1984;41(06):645–646
- 44 Heimkes B, Posel P, Stotz S, Wolf K. The proximal and distal tarsal tunnel syndromes. An anatomical study. *Int Orthop* 1987;11(03):193–196
- 45 Huynh KA, Yoon AP, Seyferth AV, Chung KC. Cost-benefit analysis of ultrasonography in the hand clinic. *Plast Reconstr Surg* 2021;147(04):894–902
- 46 Cho MJ, Kwon JG, Pak CJ, Suh HP, Hong JP. The role of duplex ultrasound in microsurgical reconstruction: review and technical considerations. *J Reconstr Microsurg* 2020;36(07):514–521
- 47 Hong JP, Hur J, Kim HB, Park CJ, Suh HP. The use of color duplex ultrasound for local perforator flaps in the extremity. *J Reconstr Microsurg* 2022;38(03):233–237
- 48 Hayashi A, Visconti G, Giacalone G, Hayashi N, Yoshimatsu H. Recent advances in ultrasound technology: ultra-high frequency ultrasound for reconstructive supermicrosurgery. *J Reconstr Microsurg* 2022;38(03):193–199
- 49 Ultrasound & Medical Imaging Certifications for physicians. APCA.org. Accessed March 20, 2022 at: <https://www.apca.org/>